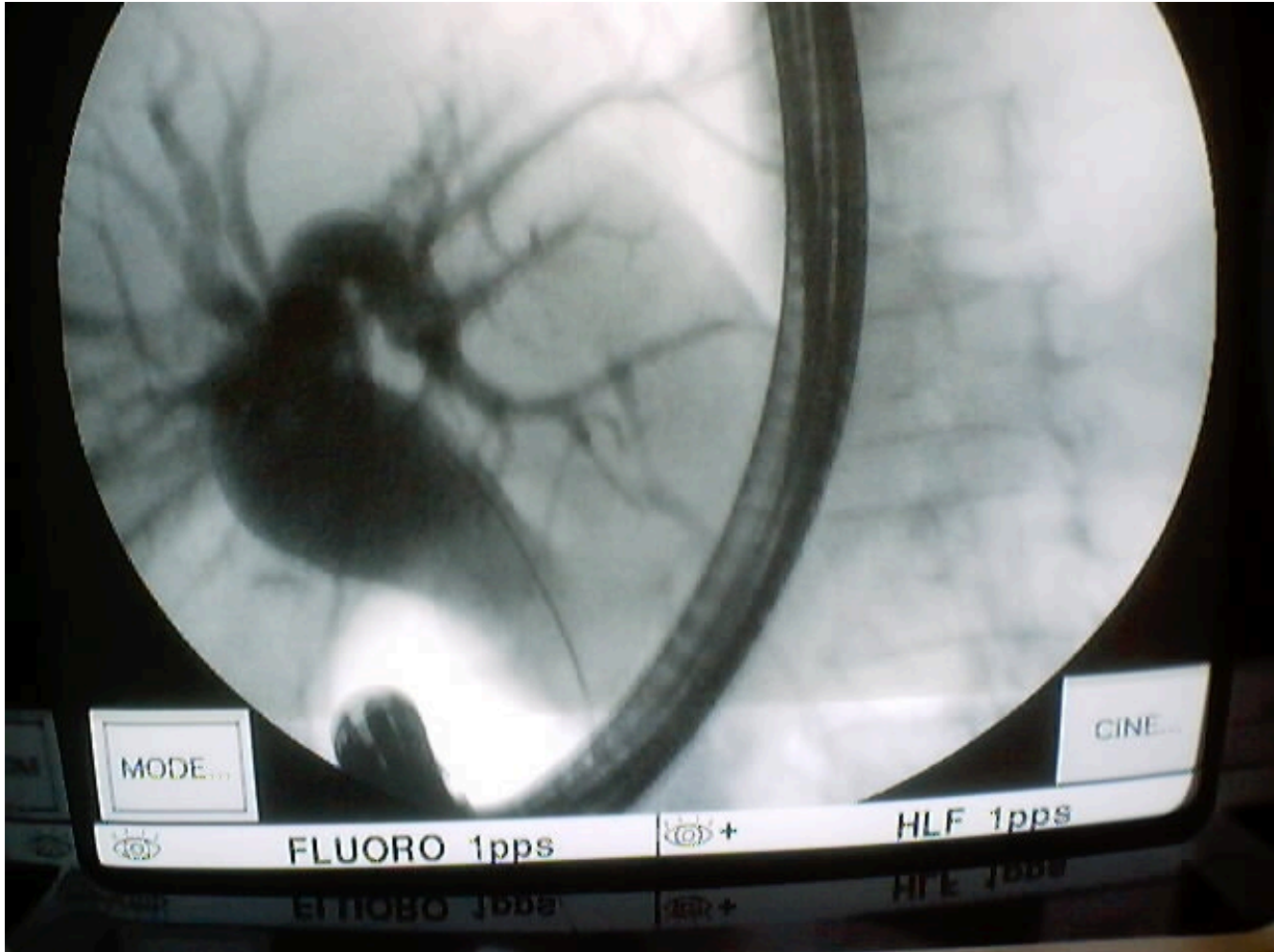


Choledochal cyst associated with gall stones

F. T. female , 40 years of age

Lap. Cholecystectomy 4 months ago for calculous cholecystitis Recurrent cholangitis occurred after the operation

U/S reported dilated CBD 1.4cm with lower CBD stones



ERCP Cholangio graphy showed massively dilated CBD typical of choledochal cyst

Endoscopic Sphincterotomy with naso-biliary drainage

No stones were retrieved

The question of further management is under discussion

Is Endoscopic Sphincterotomy enough to prevent malignancy in the future ??