

article

Open Haemorrhoidectomy : modified milligan Morgan Ligation and Excision Technique

Ghassan A Al-Nasir ; FRCS , FICS

Surgical removal offers the best chance of permanent cure for haemorrhoids⁽¹⁾ This technique is still the standard method at St Mark's hospital in London.⁽⁴⁾

The indications for this operation^(1,2,3,4)

- ③ In large (3rd degree) and moderate (2nd degree with skin tag) haemorrhoids.
- ③ When there is other anal pathology in association
- ③ As quick and perfect method to control severe bleeding from haemorrhoids.
- ③ Where other modalities of treatment have failed to cure haemorrhoids.

Preoperative measures

- ③ Sigmoidoscopy must be done to every patients with bleeding to be sure that the cause of the bleeding is the haemorrhoids.
- ③ Simple soap and waster enema two hours before surgery with cleaning and shaving of perianal skin.

Operative procedure

Under G.A. the patient is placed in full lithotomy position with the buttocks lifted over the edge of the table . the skin is painted by antiseptic and followed by toweling of the area .

- 1- A gentle two fingers dilatation of the anal canal is performed . Artery forceps are placed on the perianal skin just outside the muco-cutaneous junction opposite to each primary haemorrhoid cushion (No.3,7,11), I apply gentle traction on the forceps to bring the internal haemorrhoids into view.
- 2- As the internal haemorrhoids are pulled down, a second pair of artery forceps are placed on the main bulk of each haemorrhoidal mass. Further Traction on foreceps exposes the

Haemorrhoidal pedicles and the haemorrhoids are ready to be dissected, as fig. (1).

- 3- The haemorrhoids are divided in turn , started with No. 3 o'clock (left lateral one). The two artery forceps are held in the left hand of the surgeon with his left index finger in the anal canal pressing on the pedicle to the out. By the right hand of the surgeon using scissors , the skin at mucocataneous junction is cut in v shape manner, then the dissection of subcutaneous space is done, be ware not to injure the external or internal sphincter till the pedicle of the haemorrhoid is reached .
- 4- After traction is applied on the haemorrhoid , transfixation and ligation of the pedicle by No 0 catgut with the knot tied on the lumen side.
- 5- Control the bleeding and oozing from subcutaneous raw area by ligation or cutterization .
- 6- Now I apply a second transfixation to the pedicle proximal to the first one and suture it to the skin edge covering the row area of subcutaneous dissection by the pedicle of the haemorrhoid .
- 7- The pedicle is cut through, leaving sufficient cuff.
- 8- The other haemorrhoids are removed in a similar fashion leaving intact bridge of perianal skin and anal mucosa between each dissection side should be not less than one centimeter wide .

The three pedicles of haemorrhoids are sutured to the skin and the final appearance of the operation area are presence of 3 pedicles covering the three raw areas of dissection as in fig. (2)

Dr Ghassan AAL - Nasir ; Senior Consultant Surgeon , P.O. Box: 61078 , Medical city post office , Baghdad , IRAQ. Saddam Medical City , Baghdad , IRAQ

- 9- Cover the areas of operation by simple dressing and I do not put a pack in the anal canal.

Key points

Using second transfixation to the pedicle of haemorrhoid with catgut suture number 0 and suturing it to the skin edge has its benefit in the following points:

- 1- we did not get any slip ligature because there are two transfixation to the pedicle.
- 2- Bringing the pedicle to the skin keeping it obvious at the anal verge. So you can not miss any bleeding from the pedicle if happens.
- 3- This technique reduces the raw area and you get quicker healing.
- 4- We do not put any pack dressing only simple superficial one, so less postoperative pain and analgesia.

I used this technique for more than 1000 patients without any post operative bleeding.

References:-

- 1-Allen-Mersh T.G. , Mann C.V. , open haemorrhoidectomy (St Mark's ligation / excision method), Atlas of general surgery edited by Hugh Dudley , 3rd ed. , Chapman and Hall, London , 1996; 818-825 .
- 2-Dudly H.A.F. , Johnstone J.H.S., Rintol R.F. , operations on the rectum and anal, canal , Farquharson's textbook of operative surgery edited by Rentoul , 8th ed., Churchill livingstone , London , 1995; 468-471 .
- 3-Zollinger R.M. , injection and excision of haemorrhoids , Atlas of surgical operation edited by Zollinger, 5th ed., Collier Macmillan publishers , London , 1983; 416-417 .
- 4-McDonald P. Haemorrhoids and anal fissure, Recent advances in surgery No. 15 edited by Johnson C.D. and Taylor I, Churchill Livingstone, London , 1992; 107-117 .

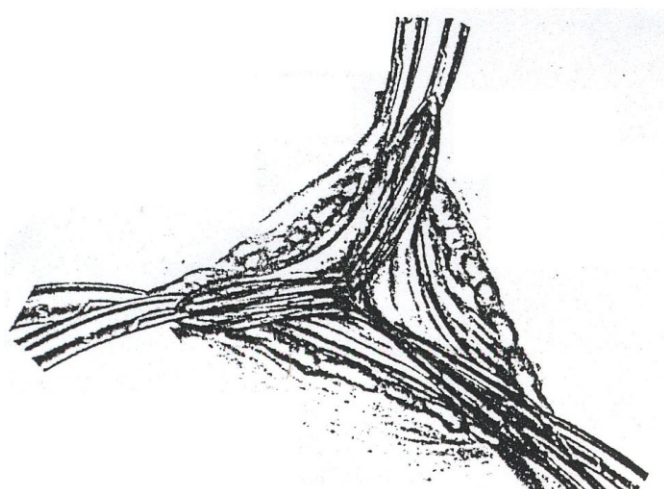


Fig (1)

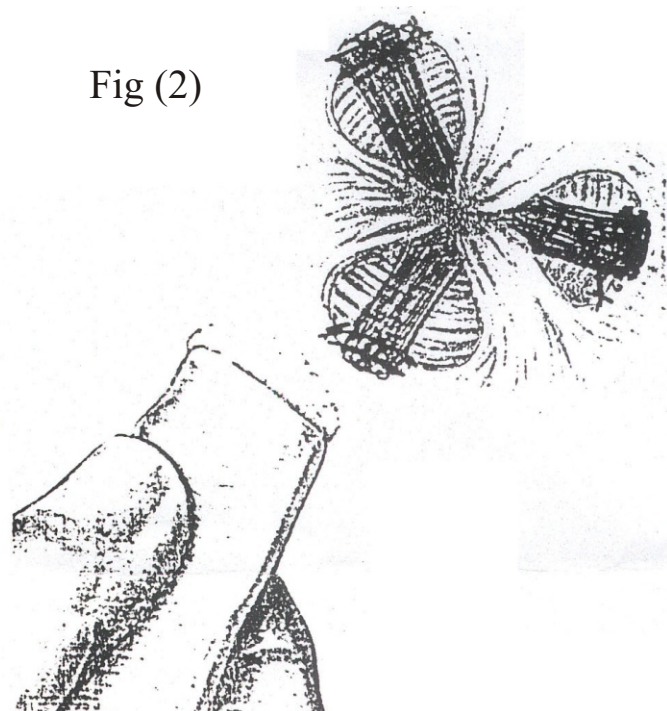


Fig (2)