

# Gall Bladder Benign Hamartomatous Polyp; Case Report

\* Luay E.Al-Khurry, MSC (path) \*\* Suhair A.Al-Salihi , FICMS (path)  
\*\*\* Khitam K.Al-Khafaji FICMS (path)

## Abstract:

A 59 years old male with a benign hamartomatous polyp in the gallbladder is reported. The patient was asymptomatic, discovered incidentally during ultrasound examination for unrelated condition.

## Case report:

A 59 years old Iraqi man arrived at the hospital in July 2003 complaining of renal colic. Abdominal radiographic examination and ultrasound studies were performed as apart of the work out for his abdominal pain. There were stones in both right and left kidneys and by accident a polypoidal mass at the fundus of the gallbladder was detected with no other remarkable finding at the common bile duct and biliary passages. All laboratory investigations were within normal. Cholecystectomy was done.

## Pathological findings:

Grossly the gallbladder measured (7 × 4) cm with a polypoidal lesion at the fundus measuring about 2cm in size.

Microscopical examination using the routine hematoxylin and eosin stain revealed features of chronic cholecystitis with a benign hamartomatous polyp that was characterized histologically by disorganized glands and crypts in a background of chronic inflammatory cells, fibrosis and irregular smooth muscle that separate the dilated crypts.

## Discussion and review of literature:

The term hamartoma refers to a mass lesion resulting from a disorderly proliferation of tissue elements normally present at that site. <sup>(1)</sup>

The prevalence of gallbladder polyps defined either pathologically or radiologically ranges from 1% 4%. <sup>(2)</sup>

In another study; polypoid lesions of the gallbladder affect approximately 5% of the adult population. <sup>(3)</sup>

Most affected individuals are asymptomatic and their gallbladder polyps are detected during abdominal ultrasonography performed for unrelated conditions.

Gallbladder polyps can be classified into either non-neoplastic lesions (which comprise 95% of all gallbladder polyps) or neoplastic lesions (of which adenomas comprise the vast majority).

The non-neoplastic polyps include:

## Cholesterol polyps:

Also known as papillomas of the gallbladder, they are not true neoplasm but rather variants of cholesterosis resulting from infiltration of the lamina propria with lipid laden foamy macrophages.

\*Dr.Luay E.Al-Khurry, Departmentt of pathology, college of medicine., Baghdad university

\*\*Dr.Suhair A.Al-Salihi, Labrotory,department,the gastroenterology & hepatology teaching hospital,Baghdad

\*\*\*Dr.Khitam K.Al-Khafaji, Departmentt of pathology, college of medicine., Baghdad university

**Adenomyoma:**

A localized form of adenomyomatosis, which usually found at gallbladder fundus and largely confined to the wall but it may project into the lumen to produce apolypoid lesion. Hyperplastic muscle layer characterizes it microscopically.

**Inflammatory polyps:**

Usually they are small sessile lesions consisting of granulation and fibrous tissue infiltrated with lymphocytes and plasma cells.

**Adenomatous polyp:**

Rare lesion, found in only 0.15% of resected gallbladders. They are typically solitary, pedunculated masses, occurring any where in the gallbladder.

Histologically, they are either papillary or non-papillary; the former consists of a branching, tree like skeleton of connective tissue covered with tall columnar cells whereas the latter consists of a proliferation of glands encased by a fibrous stroma.

Other miscellaneous polyps are extremely rare lesions with a frequency of < 0.10% in resected gallbladders. Histology includes leiomyoma, fibroma, lipoma, neurofibroma and cases of gastric heterotopias in the gallbladder were reported. In such cases the heterotopic mucosa results either in a mass, a polyp or a multiloculated gallbladder. <sup>(4), (5)</sup>

A firm diagnosis of gastric heterotopia is based on the presence of fundic mucosa replete with parietal and chief cells, a clear distinction from

intestinal metaplasia should be made but at times may be difficult. <sup>(5)</sup>

Heterotopic gastric mucosa has been described throughout the length of the gastrointestinal tract but curiously it is extremely rare in the gallbladder where it has the propensity for

causing symptoms of acute cholecystitis particularly in the young. <sup>(4)</sup>

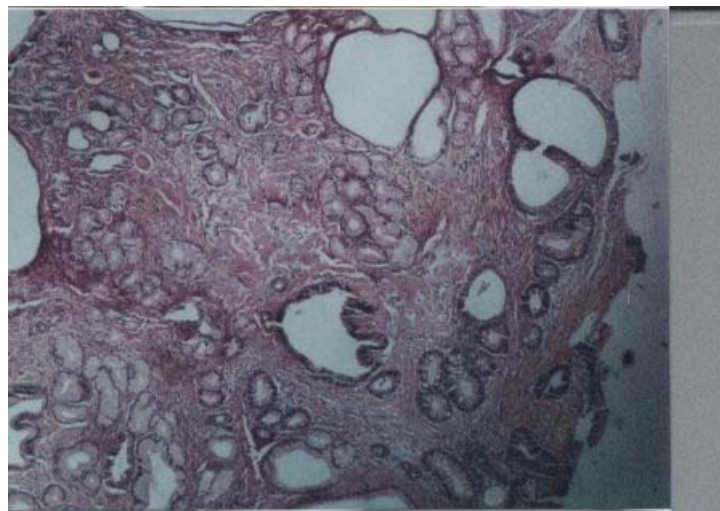
Polyps of the gallbladder do not cause symptoms except in unusual cases in which the clinical symptomatology may resemble that of biliary colic.

Rare instances of acute acalculous cholecystitis and even hemobilia have been ascribed to benign gallbladder polyps. <sup>(6)</sup>

Although the majority of gallbladder polyps are benign (most commonly cholesterol polyps) malignant transformation is a concern. The differentiation of benign from malignant lesions can be challenging. Several features, including patient age, polyp size and number and rapid growth of polyps are important discriminating features between benign and malignant polyps. <sup>(3), (7)</sup>

Resection is recommended in symptomatic patients as well as in asymptomatic individuals over 50 years of age or those where polyps are solitary, greater than 10 mm in diameter or associated with gallstones or polyp growth on serial ultrasonography. <sup>(3), (7)</sup>

Novel imaging techniques, including endoscopic ultrasonography (EUS) and enhanced computed tomography, may aid in the differential diagnosis of these lesions and permit expectant management. <sup>(3), (8)</sup>



## References:

- 1- PARAKRAMA CHANDRASOMA. GASTROINTESTINAL PATHOLOGY. APPLETON & LANGE 1999: 329.
- 2-MARK FELDMAN, LAWRENCE S. FRIEDMAN, MARVIN H.SLEISENGER. SLEISENGER&FORDTRAN'S GASTROINTESTINAL AND LIVER DISEASE :PATHOPHYSIOLOGY/ DIAGNOSIS / MANAGEMENT.VOLUME2 .2002: 1121-1129.
- 3-RP MYERS, EA SHAFFR, PL BECK. GALLBLADDER POLYPS: EPIDEMIOLOGY, NATURAL HISTORY &MANAGEMENT .CAN. J.GASTRO, 2002; 16(3): 187-194.
- 4-VALLERA DU, DAWSON PJ, PATH FR.GASTRIC HETEROTOPIA IN THE GALLBLADDER, CASE REPORT &REVIEW OF LITERATURE. PATHOL.RES.PRACT, 1992 FEB; 188:49-52.
- 5-BOYLE L, GALLIVAN MV, CHUN B, LACK EE.HETEROTOPIA OF GASTRIC MUCOSA& LIVER INVOLVING THE GALLBLADDER. REPORT OF TWO CASES WITH LITERATURE REVIEW.ARCH.PATHOL.LAB.MED.1992FEB ; 116(2): 138-142.
- 6-CAPPELL MS, MARKS M, KIRSCHENBAUM H. MASSIVE HEMOBILIA &ACALCULOUS CHOLECYSTITIS DUE TO BENIGN GALLBLADDER POLYP. DIG. DIS. SCI, 1993; 38: 1156.
- 7-YEH CN, JAN YY, CHAO TC, CHEN MF. LAPAROSCOPIC CHOLECYSTECTOMY FOR POLYPOID LESIONS OF THE GALLBLADDER. ACLINICOPATHOLOGIC STUDY. SURG. LAPAROSC. ENDOSC. PERCUTAN. TECH, 2001JUN; 11(3): 176-181.
- 8-KIMURA K, FUJITA N, NODA Y, KOBAYASHI G, ITO K.DIFFERENTIAL DIAGNOSIS OF LARGE -SIZED PEDUNCULATED POLYPOID LESIONS OF THE GALLBLADDER BY ENDOSCOPIC ULTRASONOGRAPHY. A PROSPECTIVE STUDY. J. GASTROENTEROL, 2001 SEP; 36 (9): 619-622.